

CASE REPORT

PATENT VITELLINE DUCT WITH GANGRENOUS SMALL BOWEL PROLAPSE : CASE REPORT AND REVIEW OF LITERATURE

Amezene Tadesse, MD¹, Philipos Kidane, MD¹

ABSTRACT

Vitelline duct anomalies (VDA) are rare complications of persistent omphalomesenteric duct or vitelline duct connecting the developing embryo with the yolk sac. VDA can be asymptomatic (detected incidentally) or symptomatic, most common of which is Meckel's diverticulum. A patent vitelline duct is the most common symptomatic presentation in African children and we present here a four day old neonate with patent vitelline duct with ileal prolapse. The neonate was operated with the patent vitelline duct and gangrenous ileum resected and end to end ileal anastomosis done.

INTRODUCTION

Vitelline duct or omphalomesenteric duct anomalies are secondary to the persistence of the embryonic vitelline duct, which normally obliterates by weeks 5–9 of intrauterine life. These anomalies occur in approximately 2% of the population and may remain silent throughout life, or may present incidentally sometimes with an intraabdominal complication.

Although Meckel's diverticulum is the most common vitelline duct anomaly, a patent vitelline duct is the most common symptomatic presentation in developing countries (1).

Case presentation:

A four day old female neonate was admitted to our neonatal ward after presenting with protruding mass through the umbilicus of one day duration. Mother noticed the mass protruded after the neonate cried excessively. She was passing meconium from first day onwards. She has no history of vomiting. She was born to 28 years old para II lady. The mother had regular antenatal follow up and the pregnancy was uneventful. Labor lasted 12 hrs and the delivery was spontaneous vaginal delivery.

Abdominal examination revealed fleshy pink mass protruding through the umbilical defect. There was a defect at the umbilical area measuring 3 cm in diameter. There was greenish discharge from the limbs of the protruding mass (**Fig.1**). The anal canal is well-formed and patent.

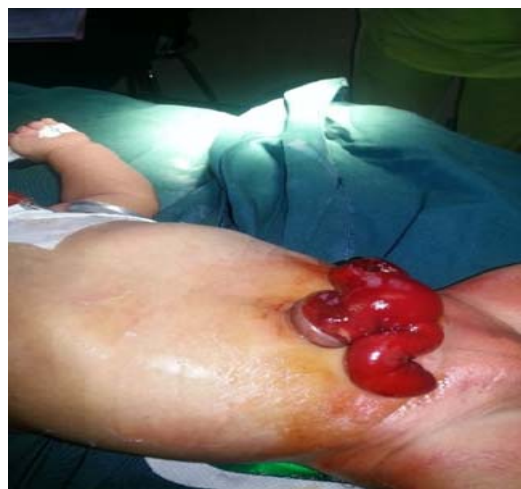

Fig. 1. Prolapsed ileum (T-shaped)

She was admitted with the diagnosis of term neonate + macrosomia + vitelline duct anomaly. She was investigated and Hematocrit was 49% and Random blood sugar 90mg/dl.

With the diagnosis of patent vitelline duct with prolapsed ileum, the neonate was operated through circum-umbilical incision. The prolapsed ileum was ischaemic with bluish discoloration (Fig.2). Majority of the prolapsed segment turned pink after warm pack. The intussuscepted ileum was reduced (Fig.3). and the distal limb was found to be gangrenous (Fig. 4) The patent vitelline duct with the gangrenous ileum around 10 cm long was resected and end to end entero-enterostomy and umbilicoplasty done. She had smooth post-operative course and discharged improved on the 8th post-operative day.

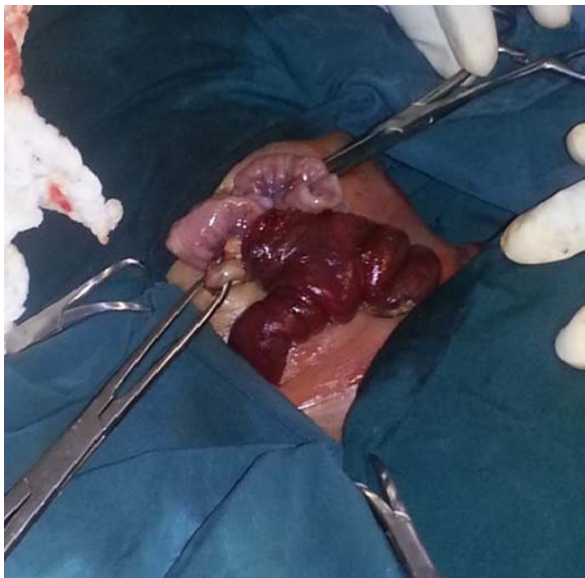


Fig. 2 Ischaemic Ileum just after circumumbilical incision

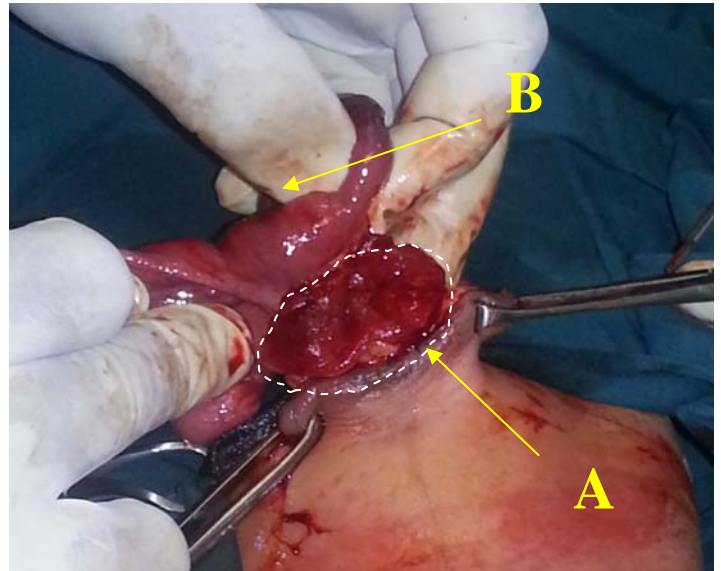


Fig. 3 Intussuscepted ileum being reduced
A -The wide patent vitelline duct
B - Intussuscepted ileum

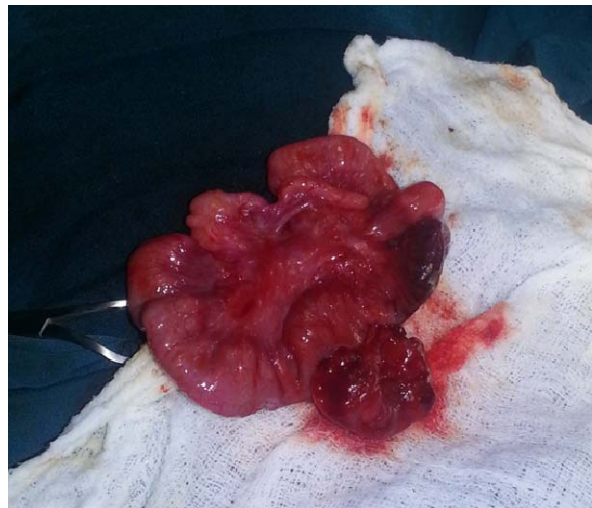

Fig. 4. Gangrenous ileal segment after reduction

DISCUSSION

Anomalies of vitelline duct occur as a result of the natural involution of the duct by 9th week of gestation. These anomalies occur in about 2% of the population(1,2). They may be silent throughout life, found incidentally or as a result of complications. The commonest symptomatic presentation is Meckel's diverticulum.

A patent vitelline duct with umbilical faecal drainage is the most symptomatic presentation of vitelline duct anomalies in developing countries(1,2). Other patterns include omphalomesenteric duct (umbilical) sinus, omphalomesenteric duct (umbilical) cyst, umbilical mucosal polyp, or a fibrous cord connecting the ileum to the umbilicus (3,4). Associated congenital anomalies include umbilical hernia, intestinal atresias, cardiac malformation, cleft lip and palate, Exomphalos, trisomy 13 and Down's syndrome(5).

Symptoms include abdominal pain, rectal bleeding, intestinal obstruction, umbilical drainage and umbilical hernia. About 6 % of these anomalies represent a patent duct and 20 % of such ducts being complicated by intussusception of the small intestine. (6) 73 % of such prolapse cases are detected during the neonatal period (6,7). The other more severe complication of such cases would be the progressive prolapse of the duct with a T or Y shaped small bowel protrusion via the umbilicus leading to mucosal ulceration and in severe cases gangrene as is evident in our case where about 10 cm of the distal prolapsed ileum was gangrenous (8, 9).

These anomalies occur in equal frequency in both males and females but the incidence of symptomatic cases is higher in males with a male to female com-

plication ratio of 3:1(2). As has been mentioned above the presence of totally patent duct with prolapsed intestine is exceedingly rare and few cases have been reported so far indicating the rarity of the condition.

Diagnosis is often with history and Physical examination usually done during the initial neonatal evaluation at birth and rarely is further investigations like ultrasound, fistulography and plain abdominal x-ray needed in complex cases (2). Hence initial thorough evaluation is vital in diagnosing such rare vitellointestinal duct anomalies and further prevents late presentation of such complicated cases of intestinal gangrene and obstruction as is seen with our neonate who presented late with ileal gangrene. Management of such anomalies need to be individualized as to the various patterns of presentation and anomalies and in emergency cases such as our neonate involves initial resuscitation followed by laparotomy often using infra- or circum- umbilical incision, duct resection and end-to-end ileoileal anastomosis(10).

Conclusion: Although rare Vitelline duct anomalies do occur and when symptomatic usually involves Meckel's diverticulum but the other less frequent variants such as the one reported here, patent duct with intestinal prolapse, could have lethal outcomes with complications like intestinal obstruction and gangrene if not detected during the initial neonatal evaluation. Management should include immediate laparotomy and resection of patent ducts after resuscitation.

ACKNOWLEDGEMENT

We would like to acknowledge Dr Abeje Chane for his role in the management and retrieval of patient information.

REFERENCES

1. Ameh EA, Mshelbwala PM, Dauda MM, Sabiu L, Nmadu PT. Symptomatic vitelline duct anomalies in children. *South Afr J Surg*2005; 43:84–85.
2. Kurt P, Schropp, MD. Meckel's diverticulum. In: Ashcraft K, Holcomb GW III, Murphy JP, eds. *Pediatric Surgery*. Elsevier Saunders, 2005, Pp 553–557.
3. Kuremu R, Jumbi G. Adhesive intestinal obstruction. *East Afr Med J* 2006;83:333- 336
4. Moore TC. Omphalomesenteric duct malformations. *SeminPediatrSurg* 1996;5:116-123.
5. Blair S P, Beasley S W. Intussusception vitello-intestinal tract through and exomphalos in Trisomy 13. *PediatrSurgInt* 4: 422-423, 1997.
6. Elebute E A, Ransome-Kuti O. Patent, vitello-intestinal duct with ileal prolapse. *Arch Surg* 91:456-60, 1965

7. Soutar SF, Douglas DM, Dennison WM. Patent vitello–intestinal duct: the risk of obstruction due to prolapse. *Br J Surg* 45: 617-20, 1958.
8. Yamada T, Seiki Y, Ueda M, et al. Patent omphalomesenteric duct : a case report and review of Japanese literature. *Asia Oceania J ObstetGynaecol* 15: 229-36, 1989.
9. Prashant N Mohite, Ashok M Bhatnagar, Virsing P Hathila1 and Jitendra H Mistry. Patent vitellointestinal duct with prolapse of inverted loop of small intestine: a case report *Journal of Medical Case Reports* 2007, 1:49 doi: 10.1186/1752-1947-1-49
10. Vane D, West K, Grosfeld J. Vitelline duct anomalies. Experience with 217 childhood cases. *Arch Surg* 1987;122:542-7