

Original Article

Acute Headaches: Patterns of MRI Findings

Abebe Mekonnen woldeyohannes¹, Tesfaye kebede legesse¹, Naomi Solomon Andarge¹, Michael Azeze Negussie²

¹Department of Radiology, College of Health Sciences, Addis Ababa University, Addis Ababa, Ethiopia
²School of Medicine, College of Health Sciences, Addis Ababa University, Addis Ababa, Ethiopia.

Corresponding author: yotam2004@yahoo.com

Abstract

Background: There is a lack of research on imaging findings of acute headaches in Ethiopia. Most available studies for cross-reference are conducted in developed countries and do not consider clinical and epidemiologic factors unique to developing countries. This study aims to identify the most common radiologic findings in patients presenting with acute headaches and examine their relationship with sociodemographic and clinical variables in an Ethiopian context.

Methodology: A cross-sectional study was adopted in this study. The brain MRI reports and files of 497 patients who were referred for the evaluation of acute headache (less than or equal to one-month duration) to Wudassie Diagnostic Center in Addis Ababa, Ethiopia, from January 2016 to September 2018 were analyzed. The demographic variables and the clinical data of the patients were correlated to the imaging findings. Data analysis was done using IBM SPSS Statistics for Windows Version 20.0.

Results: 60.6% of the patients referred for the evaluation of acute headache had abnormal MRI findings. Non-specific white matter lesions (which neither explain the reason for acute headache nor alter patient outcome and management) were the most frequently observed radiologic diagnosis (16%), followed by neoplasms (11.1%) and infections (7.7%). Tuberculoma was the most frequently diagnosed infectious cause. The majority of patients with comorbid illnesses (hypertension and HIV) had abnormal imaging findings. Age had a weak but significant positive correlation with abnormal imaging findings.

Conclusion: The findings suggest that acute headaches are frequently associated with significant underlying pathologies, particularly in older patients and those with comorbidities such as HIV or hypertension. The prominence of tuberculoma among infectious causes reflects the influence of local epidemiological factors. These results highlight the importance of targeted imaging protocols to enhance diagnostic accuracy and optimize patient management in resource-limited healthcare settings.

Keywords: Magnetic Resonance Imaging, Acute Headache, Ethiopia

Citation : woldeyohannes A, legesse T, et al. Acute Headaches: Patterns of MRI Findings Ethiop Med J 63 (1) 329-335

Submission date : 30 May 2024 **Accepted:** 21 December 2024 **Published:** 1 January 2025

Introduction

Headache disorders are among the most prevalent and disabling conditions worldwide. According to the World Health Organization (WHO), approximately 40% of the global population, or 3.1 billion people, were affected by headache disorders in 2021, with a higher prevalence in females compared to males [1]. Acute headache is a prevalent reason for emergency department (ED) visits, accounting for approximately 2.2% of all ED visits in the United States, with an estimated 2.1 million visits annually [2].

It is often challenging for physicians to determine which patients presenting with acute headaches (lasting one month or less) are candidates for neuroimaging. Certain red flag signs and symptoms identified during the history and physical examination, as well as specific types of headaches, are associated with serious intracranial pathology and therefore indicate the need for emergency neuroimaging. These red flags include sudden severe headache described by the patient as the “worst headache of my

life,” headache triggered by cough, exertion, or sexual intercourse, and headache accompanied by a change in mental status, loss of consciousness, or focal neurologic signs [2-4]. Additionally, new-onset headaches in patients diagnosed with cancer or HIV pose an increased risk of an intracranial lesion or infection [4,5].

Neuroimaging plays a pivotal role in evaluating acute headache. Common radiologic findings include subarachnoid hemorrhage, identifiable on non-contrast CT as hyperdense areas in the basal cisterns or sulci [6,7]. Intracranial masses, such as metastatic lesions, are frequently detected in cancer patients and visualized on contrast-enhanced MRI as enhancing lesions with surrounding edema [8,9]. Sinusitis with intracranial complications, such as abscess or thrombosis, is seen as sinus opacification on CT or diffusion restriction and contrast enhancement on MRI [10,11]. Cerebral venous sinus thrombosis, a cause of acute headache commonly found in young females or postpartum patients, appears on MRI with MR venography as an absence of normal venous flow [11]. Other findings include white matter changes associated with demyelinating diseases, such as multiple sclerosis, which manifest as hyperintense lesions on T2-weighted MRI [11,12]. These findings emphasize the importance of correlating clinical presentations with imaging results to improve diagnostic accuracy and patient outcomes.

The choice of imaging modality depends on clinical suspicion. The first-line imaging modality usually ordered for patients presenting with acute headaches is non-contrast CT, which can detect hemorrhage, ischemic changes, or edema [13]. However, post-contrast or non-contrast MRI is appropriate as first-line imaging in many conditions, such as new-onset headache with papilledema, cancer, or in immunocompromised patients presenting with new headache suspected of encephalitis, and sinonasal infection with feared intracranial complications [3,14]. Thunderclap headache, characterized by severe pain peaking within 60 seconds of onset, is particularly concerning for neurovascular disorders such as subarachnoid hemorrhage, ruptured aneurysm, or reversible cerebral vasoconstriction syndrome [5]. Up to 8% of patients reporting thunderclap headaches are found to have subarachnoid hemorrhage [14,15].

This study was undertaken to identify the most common radiologic findings in patients presenting with acute headaches and examine their relationship with sociodemographic and clinical variables. Given that most studies on this topic are conducted in developed countries, this research offers a critical perspective on the unique epidemiological and clinical factors influencing imaging outcomes in a developing country setting. Moreover, there is a significant gap in MRI-based studies focusing on acute head-

aches, highlighting the importance of this study in evaluating the utility, specificity, and sensitivity of MRI in diagnosing the causes of acute headaches. By addressing these gaps, this study aims to enhance our understanding of the diagnostic challenges and improve patient management in similar healthcare contexts.

Materials and Methods

Study Design and Setting

This cross-sectional study was conducted at Wudasie Diagnostic Center in Addis Ababa, Ethiopia. The study analyzed head MRI records collected from September 2016 to January 2018, using one MRI and two CT machines available for imaging services.

Sample Size

The sample size was estimated using Daniel's formula:

$$n = \frac{Z^2 p(1 - p)}{d^2}$$

where:

n = required sample size

Z = 1.96 (standard score corresponding to a 95% confidence interval)

P = 0.50 (assumed prevalence)

d = 0.05 (margin of error)

Substituting these values: $n = 384$

The calculated sample size was 384. However, to enhance the study's precision, all 497 eligible patients who met the inclusion criteria during the study period were included in the analysis.

Sampling Procedure

Data collection was conducted using a consecutive sampling method. A structured questionnaire was used to record demographic information, headache duration, and additional neurologic symptoms. The MRI reports were retrospectively reviewed. These reports were prepared by two licensed radiologists, each with over 10 years of professional experience. A nurse trained specifically for this study collected the data. All patients who met the inclusion criteria were included consecutively until the end of the study period.

Equipment (MRI machine)

MRI scanning was performed with a Siemens Magnetom C 0.35T machine, with and without contrast based on clinical indications. Imaging techniques included Axial TSE T2, Axial SE T1, Sag SE T1, Cor FLAIR, and Axial epi DWI with ADC-map. Contrast-enhanced images were acquired using gadodiamide when necessary, and interpreted by the two experienced radiologists. MRI findings were categorized as normal, minor abnormalities, or clini-

cally significant abnormalities, to identify those impacting headache etiologies or requiring further clinical action.

Operational Definitions

- **Acute headache:** Defined as a headache lasting less than or equal to one month.
- **Minor abnormalities:** These refer to non-specific findings on imaging that do not explain the cause of the headache and do not influence the clinical or therapeutic approach. Examples include nonspecific white matter changes like chronic ischemia, small arachnoid cysts, and prominent perivascular CSF spaces.
- **Clinically significant abnormalities:** These are imaging findings that directly influence the etiology of the headache or require further clinical action or intervention. Examples include neoplastic lesions, infections, and other conditions directly associated with the cause of the headache.
- **Normal findings:** Imaging results that show no abnormalities and do not contribute to explaining the headache or influence clinical or therapeutic approaches. These findings are categorized as neither minor nor clinically significant.

Variables

- **Dependent variable:** MRI findings (categorized as normal, minor abnormalities, or clinically significant abnormalities).
- **Independent variables:** Patient demographics, headache duration, associated symptoms, and comorbid illnesses.

Data Management

All collected data were reviewed for completeness before analysis. To ensure accuracy and reliability,

data were securely stored and regularly checked for inconsistencies by the research team.

Data Analysis

Data were analyzed using SPSS Version 20.0. Quantitative and qualitative comparisons were conducted using Pearson correlation and Phi correlation analyses, respectively. Statistical significance was set at $p < 0.05$. Results were presented in tables and charts as appropriate.

Ethical consideration

Ethical clearance was obtained from the Ethics and Research Committee of the Department of Radiology (with reference number DRC/001/2021), and permission to use the imaging records was granted by the Wudassie Diagnostic Center. Informed consent was not applicable as the study was retrospective with no direct patient interaction; however, the ethical committee confirmed that the data usage was ethically sound and compliant with local regulations.

Results

This study analyzed MRI data from 497 patients at Wudassie Diagnostic Center in Addis Ababa, Ethiopia (Sep 2016 - Jan 2018), focusing on acute headache evaluation. Findings highlight a patient age range of 3 to 89, with a slight female majority (56%). The average age was approximately 41 years. Most patients fell into the 18-49 age bracket. Neurological symptoms were diverse, including seizures (5.4%), vertigo (13%), and vision loss (8.7%), with nearly 39% presenting a neurological deficit like hemiplegia (13.9%), monoplegia (1%), or paraplegia (4%) (Table 1).

Table 1: Neurological signs and symptoms of patients presenting with acute headache at Wudassie Diagnostic Center, Addis Ababa, Ethiopia, September 2016 to January 2018.

Neurological signs and symptoms	Present	Absent
Seizure	27 (5.4%)	470 (94.6%)
Neurological deficit	193 (38.8%)	304 (61.2%)
Hemiplegia	69 (13.9%)	428 (86.1%)
Monoplegia	5 (1%)	492 (99%)
Paraplegia	19 (4%)	478 (96%)
Vertigo	65 (13%)	432 (87%)
Numbness and tingling	8 (1.6%)	489 (98.4%)
Decreased and/or loss of vision	43 (8.7%)	454 (91.3%)
Fever	14 (2.8%)	483 (97.2%)
Neck stiffness	6 (1.2%)	491 (98.8%)

Regarding comorbid illnesses, as shown in Table 2, most cases had no documented comorbid conditions. The most commonly documented comorbid illness was a history of hypertension, which was present in 17.1% of cases and explicitly noted as absent in 0.4% of records.

Table 2: Incidence of comorbid illnesses among patients presenting with acute headache at Wudassie Diagnostic Center, Addis Ababa, Ethiopia, September 2016 to January 2018.

Comorbid Illness	Present	Absent	Unknown
Hypertension	85 (17.1%)	2 (0.4%)	410 (82.5%)
Diabetes	37 (7.4%)	3 (0.6%)	457 (92%)
HIV	29 (5.8%)	3 (0.6%)	465 (93.6%)

Imaging Findings in Patients with Acute Headache

The imaging results indicate that 39.4% of patients had normal findings, while the remaining 60.6% had abnormal findings. Among those with abnormal imaging find-

ings, non-specific white matter lesions were the most frequently observed diagnosis (16%), followed by neoplasms (11.1%) and infections (7.7%).

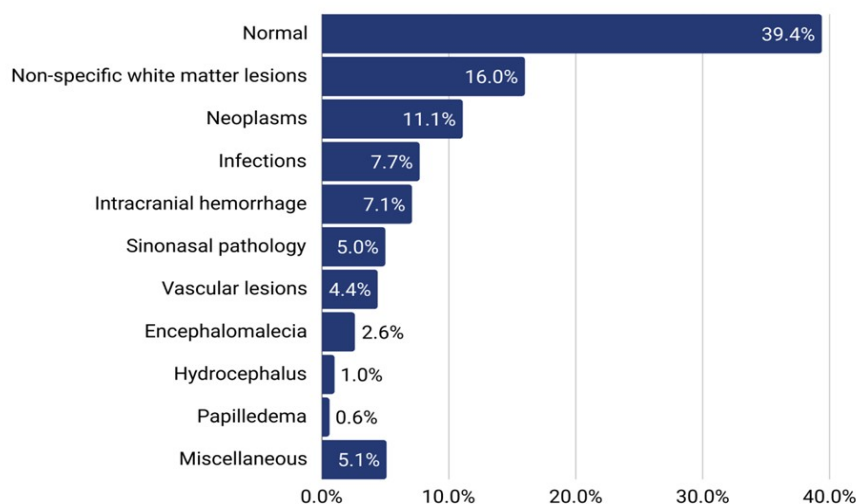


Figure 1: Radiological diagnoses of patients presenting with acute headache at Wudassie Diagnostic Center, Addis Ababa, Ethiopia, September 2016 to January 2018.

53 patients had imaging findings suggestive of tumors, including 23 with extra-axial tumors, 17 with intra-axial tumors, and 13 with pituitary adenomas. 39 patients had imaging findings indicative of infection, with 20 showing tuberculomas.

Imaging Findings in Patients with Comorbidities

Out of the 85 patients who had hypertension, 76.7% had abnormal imaging findings. Similarly, abnormal imaging results were found in 73% and 72.6% of patients with diabetes and HIV, respectively (Table 3).

Table 3: Percentage of patients with comorbid illnesses and abnormal imaging findings among those presenting with acute headache at Wudassie Diagnostic Center, Addis Ababa, Ethiopia, September 2016 to January 2018.

Comorbidities	Normal	Abnormal	Total
Hypertension	20 (23.3%)	66 (76.7%)	86
Diabetes mellitus	10 (27%)	27 (73%)	37
HIV	8 (27.6%)	21 (72.6%)	29

The most frequently found significant radiologic diagnosis for patients with hypertension, diabetes, and those with a history of trauma is intracranial hemorrhage.

For patients with HIV, however, the most frequently found radiologic diagnosis is infections (Table 4).

Table 4: Radiologic diagnoses observed in patients with hypertension, diabetes, HIV, and those with a history of trauma.

	Hypertension [%]	Diabetes [%]	HIV [%]	Trauma [%]
Neoplasms	16	4	5	5
Infection	0	4	33	3
Sinonasal pathology	3	7	5	9
Intracranial hemorrhage	19	11	5	26
Vascular lesions	8	4	19	14
Nonspecific white matter lesions	46	63	10	17
Encephalomalacia	2	4	5	17
Hydrocephalus	0	0	10	0
Papilledema	0	0	5	0
Miscellaneous	6	11	5	9

It can be seen from Table 5 below that the majority of the imaging findings (68%) were normal for patients who are less than 18 years of age. For patients who are 18-49 years of age, the majority of the findings (60%) were abnormal. For patients above 50 years, the majority (67%) had abnormal imaging findings. The correlation analysis showed a weak (Pearson correlation coefficient = 0.152) but significant

($p < 0.001$) positive correlation between age and abnormal imaging findings in general, indicating that as the age of patients increases, the likelihood of an abnormal imaging result will increase. There is no significant correlation between gender and history of trauma with imaging findings.

Table 5. Correlation between age and abnormal imaging findings in patients presenting with acute headache at Wudassie Diagnostic Center, Addis Ababa, Ethiopia, September 2016 to January 2018.

Age	Normal	Abnormal
<18	27 (68%)	13 (33%)
18-49	121 (40%)	184 (60%)
≥ 50	50 (33%)	101 (67%)
Pearson correlation coefficient	0.152	
P-value	<0.001	

When the presence of neurological symptoms is assessed in relation to imaging findings, there was no strong association identified except for fever, which

showed a significant correlation with abnormal imaging findings. The results of the Phi correlation analysis are presented in Table 6.

Table 6. Relationship between neurological symptoms and imaging findings among patients presenting with acute headache at Wudassie Diagnostic Center, Addis Ababa, Ethiopia, September 2016 to January 2018

Symptoms	Imaging findings			Phi correlation coefficient	P-value
	Normal	Abnormal	Total		
Seizure	12	15	27	-0.023	0.615
Neurological deficit	68	25	193	0.075	0.095
Numbness and tingling	2	6	8	0.039	0.387
Decrease or loss of vision	24	19	43	-0.100	0.025
Vertigo	31	34	65	-0.062	0.165
Neck stiffness	2	4	6	0.015	0.743
Fever	2	12	14	0.089	0.048

Discussion

This analysis indicates that while age and the presence of fever are significantly correlated with abnormal imaging findings in patients presenting with acute headache, other demographic variables and clinical signs, including neurologic deficits and comorbid diseases like HIV, show varied associations. The most common abnormal imaging findings are nonspecific white matter lesions, neoplasms, and infections [13,16].

Correlation analysis for comorbid illnesses like hypertension, diabetes, and HIV was limited due to the majority of patient statuses being unknown. However, it is inferred that a significant portion of patients with these conditions—73% of those with hypertension and 62% of HIV-positive patients—had abnormal brain scans. Studies consistently indicate that HIV patients with new-onset headaches are more likely to have serious brain issues. Although it is unclear whether hypertension was diagnosed at emergency departments (ED) or had a longer history, its presence at the time of the ED visit has been previously linked to brain problems. Analysis specific to HIV patients revealed infections as the most common brain scan finding, aligning with prior research highlighting infectious causes like cryptococcal meningitis and CNS toxoplasmosis, especially prevalent in patients with low CD4 counts in developing countries.

While 40% had normal brain MRIs, the remaining 60% showed abnormalities, with non-specific white matter lesions being the most common but not altering clinical outcomes. Clinically significant findings included neoplasms (11%), infections (8%), and intracerebral hemorrhage (7%), indicating a possibly more effective imaging selection or MRI's higher sensitivity over CT. This study's higher abnormal finding rates contrast with lower yields in previous U.S. studies, attributing differences to imaging criteria or MRI's enhanced sensitivity for certain conditions. Notably, extra-axial tumors were the most frequent neoplastic findings, diverging from other studies that identified bacterial meningitis and viral encephalitis

as top infectious causes, possibly reflecting epidemiologic variations in tuberculosis prevalence affecting the higher incidence of tuberculoma observed here [17].

The majority of patients had normal or minor brain MRI findings, indicating inappropriate selection criteria for imaging in patients presenting with acute headaches. The most frequently clinically important brain MRI findings in patients presenting with acute headaches are neoplasms, which is a distinct finding compared to previous studies. Older age is associated with an increased rate of abnormal imaging findings. The most common infectious cause of acute headaches was found to be tuberculoma, which shows variation from findings in previous studies, most likely due to epidemiologic differences. In HIV seropositive patients, the most common causes of acute headaches were found to be intracranial infections, which is in agreement with findings from previous studies.

Conclusion

This study demonstrates a notable correlation between age and MRI abnormalities in patients with acute headaches, suggesting increased risks of abnormalities with aging. Neurologic symptoms and comorbidities, particularly hypertension and HIV, significantly influence the incidence of abnormal imaging, with infections prevalently detected in HIV-positive patients. The high occurrence of non-specific white matter lesions and the frequent identification of neoplasms highlight MRI's vital role in acute headache assessment. Despite some inconsistencies with previous research, this study's findings advocate for improved imaging criteria tailored to patient demographics and health conditions, emphasizing a detailed approach in neuroimaging to improve diagnostic precision and patient outcomes.

Acknowledgements

The authors extend their heartfelt gratitude to Wudassie Diagnostic Center in Addis Ababa, Ethio-

pia, for their invaluable support in providing the patient's MRI reports and medical files, which were instrumental in conducting this study.

Author Contributions

Dr. A.M W: Conceptualization, Resources, Writing – Original Draft.

Dr. T.K L: Writing – Original Draft.

Dr. N S: Writing – Original Draft.

Dr. M.A N: Writing – Review & Editing.

Conflict of Interest

The authors declare no conflicts of interest.

Funding

No funding was received for this study.

Reference

1. World Health Organization. Headache disorders. Published 2021. Accessed December 25, 2024. <https://www.who.int/news-room/fact-sheets/detail/headache-disorders>
2. Goldstein JN, Camargo CA Jr, Pelletier AJ, Edlow JA. Headache in United States emergency departments: demographics, work-up and frequency of pathological diagnoses. *Cephalalgia*. 2006;26(6):684-690. doi:10.1111/j.1468-2982.2006.01117.x
3. Whitehead MT, Cardenas AM, Corey AS, et al. ACR Appropriateness Criteria® Headache. *J Am Coll Radiol*. 2019;16(11):S364-S377. doi:10.1016/j.jacr.2019.05.023
4. Longoni M, Agostoni EC. Headache in neurological emergency. *Neurol Sci*. 2020;41(Suppl 2):395-403. doi:10.1007/s10072-020-04397-7
5. Guryildirim M, Kontzialis M, Ozen M, Kocak M. Acute headache in the emergency setting. *RadioGraphics*. 2019;39(6):1739-1759. doi:10.1148/rg.2019190048
6. Edlow JA, Panagos PD, Godwin SA, Thomas TL, Decker WW. Clinical policy: critical issues in the evaluation and management of adult patients presenting to the emergency department with acute headache. *Ann Emerg Med*. 2008;52(4):407-436. doi:10.1016/j.annemergmed.2008.07.001
7. Linn FH, Rinkel GJ, Algra A, van Gijn J. Incidence of subarachnoid hemorrhage: role of region, year, and rate of computed tomography: a meta-analysis. *Stroke*. 1996;27(4):625-629. doi:10.1161/01.STR.27.4.625
8. Ramadan NM. New daily persistent headache: clinical perspective. *Headache*. 2010;50(5):748-755. doi:10.1111/j.1526-4610.2009.01461.x
9. Ward TN. Headache in patients with brain tumors: a practical approach. *Neurology*. 2000;54(3):473-479. doi:10.1212/WNL.54.3.473
10. Osborn AG. *Diagnostic Imaging: Brain*. 3rd ed. Salt Lake City, UT: Amirsys; 2010.
11. Sanei Taheri M, Ansari S, Rad HS, et al. Imaging of neurovascular disorders presenting with headache. *Neuroimaging Clin N Am*. 2010;20(3):309-325. doi:10.1016/j.nic.2010.03.007
12. Polman CH, Reingold SC, Banwell B, et al. Diagnostic criteria for multiple sclerosis: 2010 revisions to the McDonald criteria. *Ann Neurol*. 2011;69(2):292-302. doi:10.1002/ana.22366
13. Munoz-Ceron J, Marin-Careaga V, Peña L, Mutis J, Ortiz G. Headache at the emergency room: etiologies, diagnostic usefulness of the ICHD 3 criteria, red and green flags. *PLoS One*. 2019;14(1):e0208728. doi:10.1371/journal.pone.0208728
14. Edlow JA. Managing patients with nontraumatic, severe, rapid-onset headache. *Ann Emerg Med*. 2018;71(3):400-408. doi:10.1016/j.annemergmed.2017.10.022
15. Holle D, Obermann M. The role of neuroimaging in the diagnosis of headache disorders. *Ther Adv Neurol Disord*. 2013;6(6):369-374. doi:10.1177/1756285613498911
16. Bravo TP. Headaches of the elderly. *Curr Neurol Neurosci Rep*. 2015;15(6):30. doi:10.1007/s11910-015-0561-7
17. Sheikh HU, Cho TA. Clinical aspects of headache in HIV. *Headache*. 2014;54(5):939-945. doi:10.1111/head.12361