

Abebe Bekele, Samuel Tesfaye. *Ethiop Med J*, 2015, Vol. 53, No. 3

## CASE REPORT

# FATAL TRACHEO-INNOMINATE ARTERY FISTULA ASSOCIATED WITH A TRACHEOSTOMY TUBE AT A TEACHING UNIVERSITY HOSPITAL IN ADDIS ABABA: CASE REPORT AND REVIEW OF LITERATURE.

Abebe Bekele, MD<sup>1</sup>, Samuel Tesfaye, MD<sup>1</sup>

## ABSTRACT

*Tracheo-innominate artery fistula (TIAF) is a potentially lethal but rare complication associated with tracheostomy. As tracheostomies are one of the common life saving procedures that are performed routinely in the country, bring this complication to the attention of all health care professionals is of paramount importance. Hence, this case report is prepared.*

**Keywords:** Tracheostomy, Tracheo-innominate fistula

## INTRODUCTION

Tracheo-innominate artery fistula (TIAF) is a potentially lethal complication associated with tracheostomy. The survival rate in patients who develop bleeding from a tracheo-innominate artery fistula (TIAF) has been reported as 14.3%, and only patients who received immediate surgical treatment have a chance of survival. Clinical presentations and treatment of TIAF have been described mainly in the surgical literature, however, as this complication is not commonly seen in the hospital setting, early diagnosis and recognition of the subtle signs are not so easy. The intention of this case report is to present a 17 year old male patient who developed TIAF and died as a consequence of massive hemorrhage into the tracheo-bronchial tree with asphyxia at the Tikur Anbessa Hospital. We discuss the mechanisms of its development, its subtle and obvious signs as well as important diagnostic and therapeutic steps.

## CASE SUMMARY

A 17 years old male patient was admitted to the surgical ICU of the Tikur Anbessa Hospital, Addis Ababa after he was hit by car 15 hours before presentation. A diagnosis of severe traumatic brain injury

was made at admission as his Glasgow Coma Scale was 6/15 and he was immediately intubated and put on a mechanical ventilator (SIMV mode, FIO<sub>2</sub>=60). Brain CT scan revealed pontine hemorrhagic contusion with intra-ventricular extension and parietal hematoma. A thorough physical examination revealed there was no concomitant injury. He was therefore put on strict conservative management regimen.

Over the following 4-5 days, the patient started to show gradual improvement in his level of consciousness and starting from the seventh day, weaning from the ventilator was started. Ventilator mode was shifted to CPAP and on the tenth day, he was off Mechanical ventilator, but still intubated with oxygen and occasional ventilatory support. On the tenth day, a tracheostomy was done under general anesthesia and the conservative care was continued. He was showing improvement and was able to maintain oxygen saturation with atmospheric air.

On the 16<sup>th</sup> day, he suddenly cough out small amount of bright red blood mixed with secretions through the tracheostomy tube. This was considered to be due to respiratory tract irritation or infection and continuous suctioning was initiated. However, four hours after the first episode of bleeding, he developed massive bleeding through the tracheostomy tube of bright red blood. This time, a diagnosis of tracheo-innominate

artery fistula was considered: therefore, the tracheostomy balloon was over inflated, and resuscitation with crystalloid and blood transfusion was started. The bleeding was significantly reduced but didn't stop completely. Therefore, an emergency sternotomy was decided, however as the patient was being transferred to the operating theatre, he suddenly bled massively through the tube and died due to compromise of his airway.

## DISCUSSION

Tracheotomies are frequently performed procedures at the Tikur Anbessa Hospital. Review of the operation registry book show on average, 3-4 open tracheotomies are performed for varies indications. On routine basis, these patients are transferred to the Surgical ICU post operatively for a few days and then transferred to wards. Even though it is a common procedure, its outcome depends on intense post operative follow up and nursing care. Otherwise, there are dreadful early and late complications associated with its creation (1). Therefore, doctors and nurses involved in the care of these patients need to have a clear understanding of prevention and treatment of these complications.

A number of mechanisms are implicated as causes of the late complications after tracheostomy. These can be directly related to placement of the tube, leaving the tube in place for a prolonged period of time, or abnormal healing at the site of the injured tracheal mucosa (1). One of the most feared complications of tracheostomy is the development of a tracheo-innominate-artery fistula.(1-3).

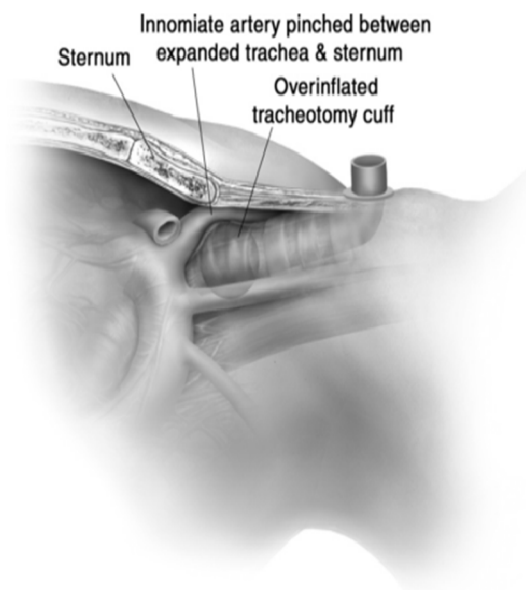
Tracheo-innominate artery fistula (TIAF) is an uncommon complication (0.1-1%) following both open and percutaneous tracheostomy (3)(4). The ultimate cause of this is pressure necrosis of the anterior tracheal wall from the tracheostomy cuff or tip, which causes erosion of the trachea and innominate artery (4,2).

In addition, low tracheostomy tube placement, over-inflation of the tracheostomy cuff, a mal-positioned tracheostomy tube tip, movement transmitted from the ventilator, local infection of a tracheostomy wound, prior radiation, steroid use, and prolonged intubation and anatomical variations of an abnormally horizontal or high innominate artery are potential risk factors (1,2,5-7). Tracheal ring fracture after percutaneous tracheostomy are also implicated in

TIFA formation (8).

Typically, the injury occurs at the 7th to 9th tracheal ring; however, given the variability of the anatomy of the innominate artery relative to the trachea, TIFA can occur at higher levels of the trachea (1,2). In most cases, the innominate artery lies adjacent to the trachea and crosses it at approximately the 9th tracheal ring. If the tracheostomy tube is placed too low, below the 3rd tracheal ring, the inferior concave surface of the cannula may erode into the artery (1,2).

Picture 1: Anatomy of Tracheo-innominate artery fistula (TIAA). This picture is adopted from Ailawadi G. Technique for Managing Tracheo-Innominate Artery Fistula. Oper Tech Thorac Cardiovasc Surg 2009 14(1):66–72.



TIFAs usually present with bleeding from the tracheostomy tube. Warning symptoms, such as aspiration of blood, bleeding beside the tracheal cannula, or pulsation of the cannula, can be absent (8). However, bleeding within the first 48 hours following insertion of a tracheostomy tube is most often due to venous injury to the anterior jugular or inferior thyroid veins (2). The vast majority of TIAFs (approximately 75%) will occur within 3–4 weeks of tracheostomy placement, but has been reported to occur many months after tracheostomy (2,5,8). The mortality rate is nearly 100% if it is not treated urgently with definitive management (4)(9). Often survival rates are 25 to 50% with this injury. Even with successful surgery, long-term survival is poor with fewer than 25% still alive at 1 year (8).

As seen in our particular patient, roughly 50% of cases have evidence of a mild sentinel bleed before the massive hemorrhage. Since this is not recognized by the care provider as something serious, or is considered to be a minor event, no major action is taken. This has happened in our patient. In patients with mild bleeding, early diagnosis is the most important factor for successful management. Rigid or flexible bronchoscopy in the operating theatre, arteriography, and CT angiography with 3D reconstruction can be helpful in the diagnosis, but these studies often fail to confirm the diagnosis due to their low sensitivity (20% to 30%) (3,4,6).

Of the various angiographic techniques, an oblique subtraction view of a selective innominate arterial injection is said to have the highest diagnostic value, although there are not enough data to assess the sensitivity and specificity of this method (4). In addition, during the acute bleeding period, bronchoscopic examination is also very difficult as the entire tracheal tree is filled with blood (2,4).

If massive hemorrhage occurs from the trachea, either through the tracheostomy tube or the airway (in 50% of cases), initial goals in the ICU are to control the airway and tamponade the bleeding while the patient is being resuscitated (2,4,5). The first maneuver is to compress the artery by overinflating the tracheal cuff and this is successful in 85% of cases. If unsuccessful and hemorrhage is ongoing, the tracheostomy incision is extended inferiorly and manual compression of the innominate artery against the posterior sternum can control the bleeding (2-5).

TIAF requires an emergency definitive surgical management. Before surgery, invasive hemodynamic monitoring is instituted in the left radial artery and a

large-bore venous access is established. The intra-thoracic structures are approached via a median sternotomy or upper hemi-sternotomy (2,5). Generally, two basic surgical management techniques have been introduced. One is maintaining flow through either direct repair of the defect or by interposition grafting, and the other is interrupting flow by simple ligation or resection of the innominate artery, while attempting to preserve the right carotid-right subclavian junction (2,4,6,8). Most authors advocate the interruption of flow by ligation of the artery because reconstruction of the innominate artery for maintaining the flow has a high risk of re-bleeding (60-80%) (2,4).

The risk of stroke is also low following innominate artery ligation because the subclavian artery is filled with significant retrograde flow from the right vertebral artery(2)(10). In this case, once identified, the innominate artery is occluded proximally and distally, the involved segment resected and the healthy intact innominate artery is over-sewn in two layers. The tracheal injury is debrided to healthy tissue and repaired with interrupted 4-0 polydioxanone suture and buttressed with a muscle flap using the sternocleidomastoid or strap muscles (2,5).

However, some reports indicate a significant risk of neurologic sequelae or vascular complications in approximately 10% of patients after innominate artery ligation and recommend to maintain adequate blood flow to the brain by first performing a right aorta-axillary artery bypass using a synthetic graft (4). An alternate approach of reconstructing the innominate artery is controversial due to a high risk of recurrent bleeding (60-86%) (5, 6). However, both approaches should be considered in the setting of severe left carotid artery stenosis/occlusion or patent right internal mammary artery bypass graft.

Recent reports have described successful percutaneous stent graft insertion to control the acute hemorrhage. In such patients, debridement and reconstruction of the innominate artery can be performed at a later time depending on the status of the patient (3,11).

Post operatively, the airway should be maintained with adequate sized endotracheal tube to allow for repeat bronchoscopy if needed, and the balloon should be seated below the site of tracheal repair. The strap muscles should be closed if possible but the skin at the tracheostomy site should be left open for dressing changes. The blood pressure should be controlled, keeping the systolic blood pressure 120 to

140 with beta-blockade to decrease the risk of stump blowout and recurrent hemorrhage (2,4,5).

In conclusion, tracheostomies are life saving basic procedures practiced in the routine general surgical set up, but their complications are serious and life threatening. Nurses and doctors involved in the care of these patients should be well informed about these complications and emergency care.

## REFERENCES

1. Epstein SK. Late Complications of Tracheostomy. *Respir Care* 2005;50 (4):542–549.
2. Ridley RW, Zwischenberger JB. Tracheoinnominate fistula: surgical management of an iatrogenic disaster. *J Laryngol Otol.* 2006 120(8):676–80.
3. Hamaguchi S, Nakajima Y. Two cases of tracheoinnominate artery fistula following tracheostomy treated successfully by endovascular embolization of the innominate artery. *J Vasc Surg.* 2012;55:545–7.
4. Seung WB, Lee HY, Park YS. Successful Treatment of Tracheoinnominate Artery Fistula Following Tracheostomy in a Patient with Cerebrovascular Disease. *Korean Neurosurg Soc* 52 2012; 547–50.
5. Ailawadi G. Technique for Managing Tracheo-Innominate Artery Fistula. *Oper Tech Thorac Cardiovasc Surg* ; 2009;14 (1):66–72.
6. Kapural L, Sprung J, Gluncic I, Kapural M. Tracheo-Innominate Artery Fistula After Tracheostomy. *Anesth Analg* 1999;88:777–80
7. Dawson D. Essential principles: tracheostomy care in the adult patient. *Nurs Crit Care.* 2014 ; 19(2):63–72.
8. Richter T, Gottschlich B, Sutarski S, Müller R, Ragaller M. Late life-threatening hemorrhage after percutaneous tracheostomy. *Int J Otolaryngol*, Volume 2011
9. Hamaguchi S, Nakajima Y. Two cases of tracheoinnominate artery fistula following tracheostomy treated successfully by endovascular embolization of the innominate artery. *J Vasc Surg;* 2012 .55(2):545–7.
10. Obatake M, Tokunaga T, Hashizume K, Mochizuki K, Nagayasu T. Prophylactic ligation of the innominate artery and creation of tracheostomy in a neurologically impaired girl: a case report. *Case Rep Med: Volume 2011*
11. Note C. Nonsurgical Treatment of Tracheoinnominate Fistula in the Pediatric Population. *Arch Otolaryngol Head Neck Surg* 133:294–6.