

ORIGINAL ARTICLE

ADNEXAL TORSION A FIVE-YEARS RETROSPECTIVE REVIEW  
IN TWO HOSPITALS

Zelege Sahlu, MD<sup>1</sup>, Shiferaw Negash, MD<sup>1</sup>, Lukman Yusuf, MD, PhD<sup>1</sup>

ABSTRACT

**Background:** Adnexal torsion remains a challenging diagnosis, often leading to delayed operative intervention and resultant ovarian loss.

**Objective:** To describe the clinical profile and therapeutic approaches of adnexal torsion in the Ethiopian setting.

**Methods:** A retrospective cross sectional descriptive chart review of women with surgically proven adnexal torsion was conducted in two teaching hospitals from Jan 1 2007- Dec 31, 2011.

**Results:** A total of 53 women with AT were analyzed. About 33(62%) of torsion occurred in the age group of 20-29 years. The most common symptoms were lower abdominal pain 52 (98.1%) followed by nausea and vomiting 46 (86.8%), whereas, the common physical findings were lower abdominal tenderness 49(92.5%) and palpable pelvic mass 40 (76.9%). Adnexal torsion was considered in the differential diagnosis upon initial evaluation only in 27 (51%) of the cases.

Of the study subjects, only 7(13.2%) had surgery within 24 hours of arrival to the facility and the mean time from initial evaluation to surgery was  $53.8 \pm 44.5$  hours. Moderately positive correlation was observed between ultrasound and intra-operative adnexal size measurement ( $r = 0.716$ ,  $p = 0.000$ ).

Using non-parametric independent sample test, none of the clinical profile categories studied show significant difference in mean time from initial evaluation to surgery. Despite the overwhelmingly benign pathology, most 46 (86.8%) of patients underwent adnexectomy with only 3(5.7%) adnexal salvage rate.

**Conclusion:** Delayed surgical intervention and low ovarian salvage rate in spite of predominantly benign pathology was observed. Therefore, high degree of suspicion, especially in patients with high risk factors, and timely intervention must be exercised in an effort to salvage the adnexae.

**Keywords:** Adnexal, Torsion

INTRODUCTION

Adnexal torsion (AT) is the fifth most common gynecologic emergency and affects females of all ages and accounts for 2.7% of surgical emergencies and 15% of surgically treated adnexal masses (1,2). Adnexal torsion is a well-known yet poorly recognized clinical entity that can involve the rotation of the tube, ovary, and ligaments either separately or together, leading to obstruction to blood flow, with subsequent ischemic necrosis of the torsed structures, unless timely intervened, results in loss of these tissues (3). Mostly, the ovary and fallopian tube rotate as a single entity around the broad ligament. Infre-

quently, the ovary and rarely the fallopian tube may twist alone around their mesentery (4).

Adnexal torsion can occur at any age, but mostly occurs in the early reproductive years. The median age reported by a large review was 28 years, with the percentage of patients younger than 30 years is approximately 70-75%. Functional cysts and benign neoplasm accounted for 94% of the cases, with the remainder occurring in the setting of normal appearing ovaries (5). Adnexal torsion has been attributed to a variety of etiologies. Certain causes are more likely in particular age groups; while anatomic factors usually account for AT in adults, normal ovaries have been demonstrated in over 50 percent of AT in children under the age of 15 years (1).

<sup>1</sup>Department of Obstetrics and Gynecology, Collage of Health Sciences Addis Ababa University

Though, confident and early diagnosis of adnexal torsion is imperative, failure to consider it in the differential diagnosis is not uncommon, given the relative infrequency of this condition. Consideration is particularly crucial in a patient with known risk factors for the disease, such as ovarian mass, prior pelvic surgery, or pregnancy (6).

The diagnosis of AT can be challenging, because the symptoms are relatively non-specific. A definitive diagnosis of adnexal torsion is based upon surgical findings. The clinical diagnosis should be considered in girls or women with lower abdominal pain, especially in the setting of ovarian cyst/mass, and is primarily a clinical judgment that utilizes imaging modalities as adjuncts to complete the clinical picture (1, 7-10). In a review of fifty-nine patients with AT, the two most common presenting features were lower abdominal pain and adnexal mass, 83% and 72% respectively (10).

Delayed presentation of women resulting in loss of the adnexa due to irreversible damage was shown in a retrospective chart review among 87 surgically confirmed adnexal torsion cases, where, detorsion and salvage was possible only in 8 (9%) patients, and 26 (29.2%) patients had surgery within 24 hours (6). Ovarian salvage rate of 0% to 7 % reported by other studies (7, 8). Therefore, the mainstay of treatment is swift operative evaluation to preserve ovarian function and prevent infectious complications. Historically, removal of the affected adnexa had been the standard treatment of the torsed adnexa, because, it was believed that restoring normal anatomy via detorsion could dislodge a clot in the ovarian vein and subsequent embolism, or leave a necrotic vestige. Despite this pervading theory, there is growing evidence that unwinding the involved adnexa to observe for tissue reperfusion and viability is safe, and currently the minimally invasive surgical management of adnexal torsion has been increasing in efficacy (5,11-16).

Multiple reports over the past 15 years have described minimally invasive procedures that detorsed and preserved the ovary without the hypothesized adverse sequelae and with return of normal hormonal function and fertility. These and other data suggest that detorsion and ovarian preservation is a safe operation that should be considered in premenopausal patients (6, 17-25). In addition, histopathology of the torsed adnexa was reported to be benign in over 90%, and hence, benign neoplasms are more likely to undergo torsion than malignant ovarian neoplasms (16, 17).

In a retrospective review of all women less than 40 years old with adnexal torsion, all potentially viable adnexa were untwisted, and cystectomies were performed unless the adnexa failed to reperfuse. Of the ninety-four women studied, 61(65%) received ovarian cystectomies and 33(35%) underwent salpingo-oophorectomy. No thromboembolic complications or increase in post-operative morbidity was seen. Patients requiring salpingo-oophorectomy had more pre-operative fever and leukocytosis, larger masses, and higher degrees of torsion (26). Therefore, the paradigm has now shifted from one of ovarian removal to one of ovarian evaluation and likely preservation, even in the face of a dusky, seemingly necrotic appearance. However, the diagnostic dilemmas and difficulties in preserving the ovaries in lately appearing women is still of major concern(1).

There is no study so far conducted in Ethiopia regarding adnexal torsion. The objective of this study is therefore, to describe the demographic characteristics, clinical profile, imaging and laboratory findings, possible causes, diagnostic challenges, and mode of management in women with surgically proven AT.

## MATERIALS AND METHODS

A cross sectional retrospective descriptive study was conducted in the two hospitals, Tikur Anbassa Hospital and Saint Paul's Hospital, which are specialized referral and teaching hospitals in Addis Ababa, used by the Department of Obstetrics and Gynecology, College of Health Sciences, Addis Ababa University, for both undergraduate and postgraduate training programmes. These hospitals serve as the main referral centres in the city and its vicinity, with 24 hours multi-disciplinary specialty care, provided by residents with specialist supervision, for all gynecologic and surgical emergencies. In addition, the two hospitals carry out about 1200 major gynecologic surgeries per year, have an intensive care units and blood transfusion facilities, with experienced consultants in the field of Obstetrics and Gynecology as well as Anesthesiology. Gandhi Memorial Hospital (GMH), a maternity referral hospital under the Addis Ababa City Administration Health Bureau, was excluded from the study, as women presenting with acute abdomen accompanied with diagnostic dilemmas were referred to the aforementioned hospitals. In addition, as a preliminary assessment, review of GMH major operation registry book was done and only one surgi-

cally confirmed case was found over the five years study period.

The study design was a five years retrospective chart review, conducted from Jan1, 2007 – Dec 31, 2011, involving all women who visited the study sites during the study period, with surgically confirmed cases of AT, or women for whom AT was considered as a differential diagnosis on initial examination if evaluation note is accompanied by time, initial laboratory or imaging requests or anything on the card suggesting its precedence over the other evaluation. Subjects were excluded if AT was not confirmed surgically or torsion of paratubal or paraovarian cyst or mass was not involving the ovaries.

Using structured checklist prepared in English, data was collected by trained Obstetric and Gynecology residents on the variables of interest. The major operation theatre registries of the hospitals were used to retrieve card numbers of the study subjects, and then patients' cards were collected from the card rooms of the respective hospitals. Data was checked for completeness, consistency, and accuracy, then, analyzed using SPSS version 20 statistical software. Frequency distribution tables, mean, and median were used where appropriate to describe quantitative variables, whereas charts and proportions were used to describe qualitative variables. Non-parametric Independent Samples T-test and Bivariate correlations were used to measure associations, with 95% confidence level and level of significance set at  $\alpha = 5\%$ .

Ethical clearance was obtained from research and publication committee of the Department of Obstetrics and Gynecology, College of Health Sciences, Addis Ababa University. Permission to conduct the study in the chosen hospitals was secured from responsible bodies. Information in the charts were used solely for the current research purposes, and names of patients' or card number were not described in the study.

## RESULTS

Over a period of 5 years, a total of 73 charts were identified from major operation registry books, 48 from Saint Paul's and 25 from Tikur Anbessa Hospitals. Of these, 53 cards with surgically confirmed adnexal torsions were retrieved, 38 (71.7%) from SPH and 15 (28.3%) from TAH. Torsed paraovarian/paratubal cysts or masses in which the ovary was uninvolved ( $n = 3$ ) were excluded so as not to improve ovarian salvage rates falsely; the rest, 17 charts could not be located.

The age distribution ranges from 17-75 years with median of 26 years. Thirty three (62%) of the AT occur in the age group of 20-29 years, and 38 (73.6%) of AT occur in the age groups of 29 years and below. Majority 36 (68%) are from Addis, 20 (37.7%) are married, and 16 (30.2%) being single (Table 1).

The patients' symptom characteristics were variable. Lower abdominal pain was manifested in 52 (98.1%) and nausea and vomiting accounted for 46 (86.8%) of patients with AT. History of previous surgeries, cesarean sections, were reported only in 2 (8%) of the subjects.

Among 34 patients who had their temperature recorded, only 8 (23.5%) had objective record of fever. Lower abdominal tenderness and palpable pelvic mass were reported in 49 (92.5%) and 40 (76.9%) of patients, respectively. Adnexal torsion was considered in the differential diagnosis upon initial evaluation only in 17 (32.1%) patients, the rest being either not reported or documented (Table 2). The statistical association of pelvic pain, nausea and vomiting, fever, lower abdominal tenderness, and palpable adnexal mass, were compared with the presence of adnexal torsion in the initial differential diagnosis, but due to small observations, no valid result could be generated.

Table 1. Socio-demographic characteristics of women with adnexal torsion, TASH and SPH, Jan 1, 2007-Dec 31, 2011

Characteristics	Value	Number (N=53)	Percent
<b>Address</b>	Addis Ababa	36	67.9
	Out of Addis	17	32.1
<b>Age</b>	15-19	6	11.3
	20-24	14	26.4
	25-29	19	35.9
	30-34	4	7.5
	≥35	10	18.9
<b>Occupation</b>	Housewife	12	22.7
	Student	5	9.4
	Gov't / self-employees	8	15.1
	Not documented	28	52.8
<b>Marital Status</b>	Single	16	30.2
	Married	20	37.7
	Divorced /widowed	6	11.3
	Not documented	11	20.8

\* Government employees, self employees and daily laborer    \*\* Divorced and widowed

Table 2 – Clinical Presentation of Patients with Adnexal Torsion, TASH and SPH, January 1, 2007- December 31, 2011.

Symptoms and Signs		Frequency (n = 53)	Percent
Pelvic pain	Yes	52	98.1
	No	1	1.9
Nausea and vomiting	Yes	46	86.8
	No	7	13.2
Pelvic surgery	Yes	2	3.8
	No	51	96.2
Fever	Febrile	8	15.1
	Afebrile	26	49.1
	Not documented	19	35.8
Adnexal tenderness	Yes	49	92.5
	No	4	7.5
Palpable Adnexal Mass	Yes	40	75.5
	No	12	22.6
	Not documented	1	1.9
Adnexal torsion Diagnosis	Yes	17	32.1
	No	16	30.2
	Not documented	20	37.7

Of the study subjects, 13 (24.5%) were pregnant, with gestational age that ranges from 6-27 weeks, of which, 10 (77%) were first trimester pregnancies. Of the 48 (90.6%) study subjects, who had ultrasound examination, 44(91.6%) had abnormal results (cyst, solid or complex mass), and in 4 (8.6%) patients' ultrasound results was non-revealing. The size of the mass measured by the ultrasound ranges from 5-20 cm with the mean of  $8.5 \pm 3.2$  cm, and 27 (59.1%) of AT had a mass with a size between 6-8 cm (Fig. 1). Doppler study together with ultrasound was done only in 3 (6.3%), of which, only one showed compromised vascular flow (absent vascular flow). Despite this, most appeared gangrenous on laparotomy, and, adnexectomy was performed.

The time interval from the onset of symptoms to arrival for evaluation by health professional ranged from 4-96 hours, with the mean of  $21.6 \pm 19.2$  hours. Only 14(26.4%) patients with AT arrived within 24 hours, and 7 (13.2%) patients had surgery within 24 hours after arrival to the facility. The mean time from initial evaluation to surgery was  $53.8 \pm 44.5$  hours (range = 4 to 168 hours), and similarly, duration of time spent from onset of symptom to surgery (range= 10 - 192 hours), mean,  $74.7 \pm 46.3$  hours.

Non-parametric Independent Samples (Mann Whitney U) test was used to check if presence or absence of clinical manifestations, pregnancy test, and ultrasound result were different in mean time from initial evaluation to surgery. However, none of clinical profile categories had statistically significant difference in mean time from their counterparts. Pelvic pain ( $p = 0.067$ ), nausea and vomiting ( $p = 0.883$ ), fever ( $p = 0.401$ ), adnexal tenderness ( $p = 0.647$ ), diagnosis of adnexal torsion on initial evaluation ( $p = 0.058$ ), pregnancy test ( $p = 0.691$ ), ultrasound result ( $p = 0.621$ ).

When intra-operative finding were considered, majority, 31 (58.5%) occurred on the right side and the rest occurred on the left, and, almost all, 52 (98.1%) appeared gangrenous, the remaining one was not documented. The median degree of adnexal torsion was 720. In this study due to the low salvage rate, association couldn't be computed. Regarding consistency of the adnexae, 38 (71.7%) were cystic followed by 10 (18.9%) solid. The intra-operative mass size ranges from 4 – 24 cm, with the mean of  $10.8 \pm 4.3$  cm (Table 3).

Table 3 - Intraoperative Findings and operative procedures of Patients with Adnexal Torsion, TASH and SPH, January 1, 2007-December 31, 2011.

Intraoperative Findings		Frequency (n = 53)	Percent
Side of adnexal torsion occurred	Right	31	58.5
	Left	22	41.5
Consistency of torsed adnexa	Cystic	38	71.7
	Solid	10	18.9
	Complex	5	9.4
Appearance of torsed adnexa	Gangrenous	52	98.1
	Not documented	1	1.9
Attempt of detorsion	Yes	8	15.1
	No	45	84.9
Adnexal salvage	Yes	3	5.7
	No	50	94.3
Type of procedure done	Adnexal salvage with resection of tumorous mass	3	5.7
	Oophorectomy	3	5.7
	Salpingectomy	1	1.9
	Adnexectomy	46	86.8

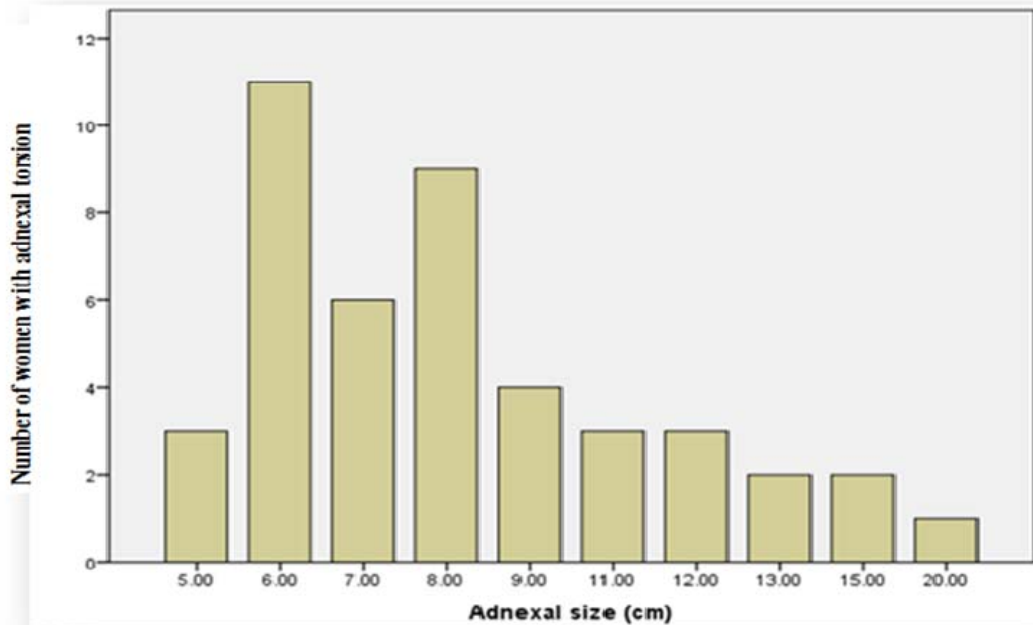


Figure 1 - Size of Torsed Adnexae Measured by Ultrasound, TASH and SPH, January 1, 2007- December 31, 2011.

The mean adnexal size was  $10.8 \pm 4.3$  cm versus  $8.86 \pm 3.29$  cm in the intra-operatively estimated and transabdominal measurement, respectively. Using Nonparametric Spearman's correlation, the pre-operative ultrasound and intra-operative adnexal size measurements show moderate positive correlation,  $r = 0.716$ ,  $p < 0.000$  (Figure 2).

Adnexectomy was the commonest procedure 46 (86.8%) performed for the patients. Detorsion was performed in 8 (15.1%) patients, and, only 3(5.7%) of these patients had resection of an accompanying cyst or complex neoplasm with salvage of the adnexa (Table 3).

From 39 (73.6%) pathology results available, the resultant histologic types were: functional cysts, 18 (46.2%), necrotic or edematous ovarian tissue with no identifiable underlying pathology and benign neoplasms each contributing to 10 (25.6%), and only 1(2.6%) reported to be malignant (serous cystadenocarcinoma) (Table 4).

There was no immediate complications encountered following detorsion or adnexal salvage, though, subsequent ovarian viability in these patients was not ascertained.

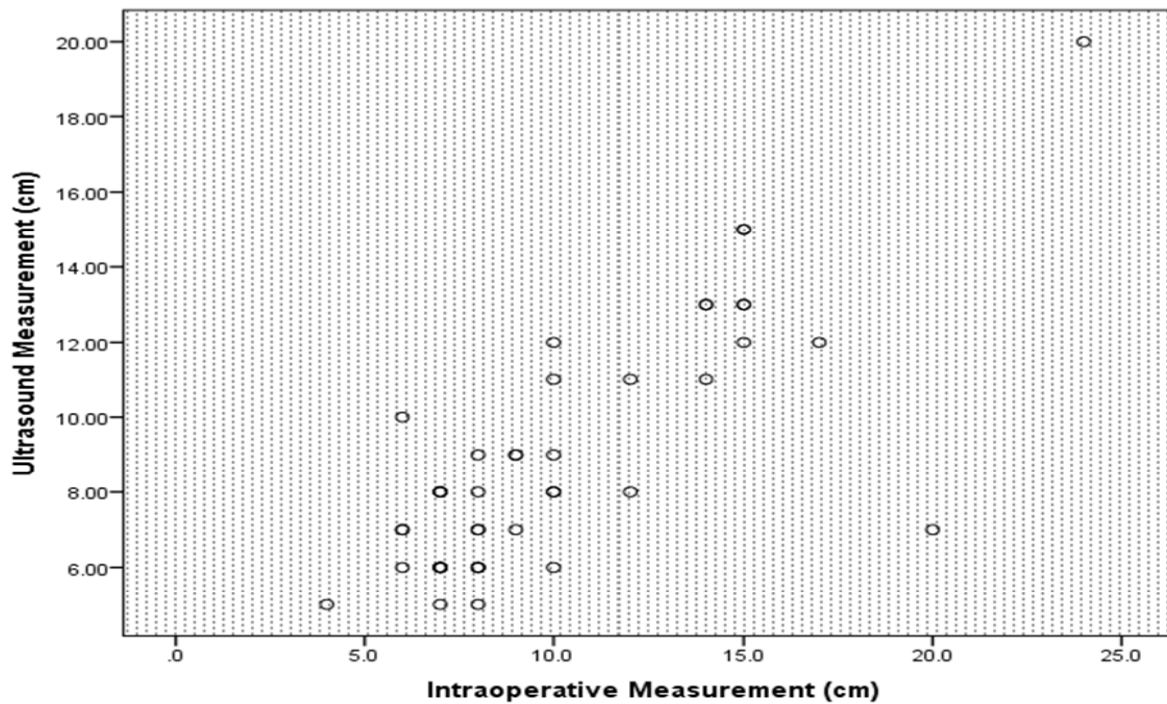


Figure 2 - Scatter Diagram Showing Moderate Positive Correlation of Preoperative Ultrasound and Intraoperative Adnexal Mass Measurements, TASH and SPH, January 1, 2007-December 31, 2011.

Table 4 – Pathologic Classification of Torsed Adnexae, TASH and SPH, January 1, 2007- December 31, 2011.

Pathology result	Frequency (n = 53)	Percent
Necrotic/infracted tissues	10	18.9
Cystic (functional)	18	34.0
Serous cystadenomas	6	11.3
Mucinouscystadenomas	1	1.9
Dermoid cyst	2	3.8
Benign Brenner tumor	1	1.9
Serous cystadenocarcinoma	1	1.9
Not documented (pathology result not available)	14	26.4

## DISCUSSION

Adnexal torsion was considered in the initial differential diagnosis in nearly a third of the cases in our study. Thus, it appears from many studies, including ours, the majority of patients with AT have a delayed diagnosis due to the non-specific nature of the clinical presentations (1, 7-9).

Similar to other reports, our study revealed that about 62% of adnexal torsion occurrence in the age group of 20-29 years. This best describes the teaching that age is a strong corollary for hormonal development, which can influence the incidence of torsion caused by ovarian cysts. Reproductive age women were shown to have the highest incidence of ovarian torsion. This is likely to be related to the higher frequency of physiological and pathological ovarian neoplasms, infertility therapy, and pregnancy in this age group compared to younger or older females (5, 15).

The commonest clinical presentations observed in our patients; lower abdominal pain, nausea and vomiting, lower abdominal tenderness, and palpable pelvic mass were similar to other studies (10). Objective findings were also variable and rarely impressive in patients with AT. In fact, this paucity of objective findings may be a clue that AT should be considered. Although ovarian necrosis can cause leukocytosis and fever; laboratory abnormalities were non-diagnostic and WBC count were unremarkable in the majority of patients in our study, as was temperature derangement.

As physical examination findings are often non-specific, imaging studies are frequently used in the evaluation of a patient with lower abdominal pain. Ultrasound is the imaging modality of choice for adnexal torsion, as it is non-invasive and avoids radiation exposure. In this study, ultrasound detected 91.7% of enlarged adnexa associated with AT. Admittedly, in our study, all ultrasound studies were done via a transabdominal approach, although, obesity or extreme abdominal tenderness can limit the study and may have impacted the sensitivities. But the sensitivity of doppler flow studies of the ovaries has yet to be determined. Any flow found in the

ovary by duplex can delay operative intervention. Although doppler flow imaging with morphologic assessment (e.g., ovarian masses) has been reported to improve the accuracy of diagnosing AT, our study found out that doppler flow still missed 2 of the 3 patients with AT (5, 8).

The observed preferential sidedness of torsion to the right in our study is in agreement with the expected 3 to 2 ratio (right to left) and has been attributed to the relative mobility of the cecum allowing for more ovarian movement, in comparison to the relative fixation of the sigmoid colon (8). Contrary to the current recommendation of detorsion of all potentially viable ovaries and subsequent ovarian salvage rate of 9-65% by various investigators, our study demonstrated only 15% detorsion and 5.7% ovarian salvage rate (4, 18, 25).

Among patients whose adnexae were salvaged, only one underwent surgery within 24 hours after the onset of symptoms, the rest were done 2.5 to 5 days later. Only 2 (3.8%) patients had surgery within 24 hours of arrival to the hospital. This can be explained with both the patients' and the health care providers' delay; for the patients, the onset of symptom may assume milder form not urging to seek health care, and for the health care provider, it is obviously due to the associated diagnostic confusion. Another study revealed a significant association between waiting periods for surgery more than 10 hours and diagnosis of adnexal necrosis. The contemporary philosophy for salvaging the ovary when at all possible, stems from concerns of decreased fertility as a result of the loss of even a single ovary because of decreased ovarian reserve and a reduced reproductive life span. The low ovarian salvage rate observed in our study limits our ability to find statistical correlation between salvage and other metrics (clinical presentation, imaging, and laboratory study time to surgery) (6, 17-24).

Malignancy as a source of the enlargement in most series is rare. This was supported by our finding, where, 97.4% of the pathology were simple cyst or benign tumors. Similar result was reported from a review of histopathology of the torsed adnexa, where, over 90% were benign, and hence benign neoplasms are more likely to undergo torsion than malignant ovarian neoplasms (16, 17). There is so far no laparoscopic approach was made both for diagnosis and treatment in this study, despite the fact that it is of paramount importance in salvaging the adnexa and clearing the diagnostic confusion (16-18).

**Conclusion and recommendations:** Ovarian torsion remains a diagnostic dilemma and a diagnosis of exclusion. This study demonstrated strong association of torsion with a pelvic mass larger than 5 cm measured by ultrasound in 92% of cases. Therefore, with coexistence of one or more clinical profiles (pain, nausea and vomiting, abdominal tenderness and pregnancy), it is prudent to consider diagnosis of adnexal torsion and expedite surgical management in an effort to preserve ovarian function and prevent adverse sequelae (necrosis, infarction, local hemorrhage, peritonitis, and systemic infection). A 2% risk of malignancy in the torsed ovaries combined with the commonly affected age being young, supports the implementation of detorsion at initial operation.

As this study is the first of its kind, its contribution towards the knowledge of AT in the country can not be undermined. However, the study population can neither be representative of the population of the city nor the country, as these hospitals manage more complicated cases. Some data retrieved from the cards were incomplete because of the nature of the study design (retrospective), we therefore, recommend a prospective large scale study in the future. We further recommend the use of minimally invasive surgical technique, for women presenting with acute abdominal pain and a pelvic mass which might help shorten the prolonged presentation to surgery time and help salvage the adnexae.

## ACKNOWLEDGEMENTS

We would also like to thank the Research and Publication Committee of Obstetrics and Gynecology, College of Health Sciences, AAU, for approval and readiness for provision of ethical clearance. Furthermore, we acknowledge the hospital directors of the study sites for having accepted the ethical clearance letter and allowing us to undertake the study.

We extend our heartfelt gratitude to Tsion Sahle, secretary in the Department of Obstetrics and Gynecology, for her ever welcoming approach and enthusiasm to assist us in the secretarial work. Finally, we are indebted to card room workers of the respective hospitals for assisting in the chart retrieval activity.

## REFERENCES

1. Growdon WB., Laufer MR. Ovarian and Fallopian Tube Torsion. June 2, 2011; March 20, 2012; <http://www.uptodate.com/contents/ovarian-and-fallopian-tube-torsion>
2. Bouguizane S, Bibi H, Farhat Y, Dhifallah S, Darraji F, Hidar S, et al. Adnexal torsion: a report of 135 cases. *J Gynecol Obstet Biol Reprod* 2003; 32(6):535-40.
3. Debra H. Ovarian Torsion: A Fifteen-Year Review. *American College of Emergency Physicians* 2001; 38 (2):156-9.
4. Hoffman L. Pelvic Mass In: Schorge O, Schaffer I, Halvorson M, Hoffman L, Bradshaw D, Cunningham F. (eds), *Williams Gynecology*, New York, The McGraw-Hill Companies, Inc,2008.
5. Varras M, Tsikini A, Polyzos D, et al. Uterine adnexal torsion. Pathologic and gray-scale ultrasonographic findings. *Clin Exp Obstet Gynecol* 2004;31(1):34-8.
6. Fleischer C. Ovarian Torsion. Sep 26, 2011 to Mar 23, 2012; <http://www.emedicine.medscape.com/article/ovarian-torsion-to-be-omitted>.
7. Way S. Ovarian cystectomy of twisted cysts. *Lancet* 1946; 2:46-7.
8. Albayram F, Hamper UM. Ovarian and adnexal torsion. Spectrum of sonographic findings with pathologic correlation *J Ultrasound Med* 2001;20(10):1083-89.
9. Argenta PA, Yeagley TJ, Ott G, Sondheimer SJ. Torsion of the uterine adnexa. Pathologic correlations and current management trends. *J Reprod Med* 2000;45(10):831-36.
10. Bayer AI, Wiskind AK. Adnexal torsion: can the adnexa be saved? *Am J Obstet Gynecol* 1994;171(6):1506-10.

11. Gorkemli H, Camus M, Clasen K. Adnexal torsion after gonadotrophin ovulation induction for IVF or ICSI and its conservative treatment. *Arch Gynecol Obstet* 2002;267(1):4-6.
12. Haskins T, Shull BL. Adnexal torsion. *South Med J* 1986; 79:576-77.
13. Hibbard LT. Adnexal torsion. *Am J Obstet Gynecol* 1985; 152:456-61.
14. Rock, John A. Jones, Howard W. *TeLinde's Operative Gynecology*, Philadelphia, Lippincott Williams & Wilkins, 2008, 10th ed, 637-38.
15. Berek, Jonathan S. *Berek & Novak's Gynecology*, 14th Edition, Philadelphia: Lippincott Williams & Wilkins, 2007, 14<sup>th</sup>ed, 482.
16. Promecene PA . Laparoscopy in gynecologic emergencies. *Semin Laparosc Surg* 2002; 9(1): 64-75.
17. Harkins G. Ovarian torsion treated with untwisting: second look 36 hours after untwisting. *J Minim Invasive Gynecol* 2007; 14:270.
18. Shalev E, Bustan M, Yarom I, Peleg D. Recovery of ovarian function after laparoscopic detorsion. *Hum Reprod* 1995;10(11):2965-66.
19. Anders JF, Powell EC. Urgency of evaluation and outcome of acute ovarian torsion in pediatric patients. *Arch Pediatr Adolesc Med* 2005;159(6):532-35.
20. Aziz D, Davis V, Allen L, Langer JC. Ovarian torsion in children: is oophorectomy necessary? *J Pediatr Surg* 2004; 39(5):750-53.
21. McGovern PG, Noah R, Koenigsberg R, Little AB. Adnexal torsion and pulmonary embolism: case report and review of the literature. *Obstet Gynecol Surv* 1999;54(9):601-8.
22. Oelsner G, Cohen SB, Soriano D, Admon D, Mashiach S, Carp H. Minimal surgery for the twisted ischaemic adnexa can preserve ovarian function. *Hum Reprod* 2003;18(12):2599-602.
23. Rody A, Jackisch C, Klockenbusch W, Heinig J, Coenen-Worch V, Schneider HP. The conservative management of adnexal torsion--a case-report and review of the literature. *Eur J Obstet Gynecol Reprod Biol* 2002;101(1):83-6.
24. Zweizig S, Perron J, Grubb D, Mishell DR. Conservative management of adnexal torsion. *Am J Obstet Gynecol* 1993;168(6.1):1781-95.
25. Sommerville M, Grimes DA, Koonings PP, Campbell K .Ovarian neoplasms and the risk of adnexal torsion. *Am J Obstet Gynecol* 1991;164(2):577-8.
26. McHutchinson LL, Koonings PP, Ballard CA, d'Ablaing G. Preservation of ovarian tissue in adnexal torsion with fluorescein. *Am J Obstet Gynecol* 1993 May;168(5):1386-88.